

Orbital Cellulitis Secondary To Spheno Ethmoidalsinusitis Complicating Septic Thrombosis Of Right Superior Ophthalmic Vein And Anterior Cavernous Sinus: A Case Report

Dr.E.Rama devi M.S¹, Dr. B K Jain M.S², Dr. V.Muralikrishna M.S³, Dr.E.Anupama (MS)⁴

¹Asst.Prof.Department of Ophthalmology,
Rangaraya Medical college,Kakinada
erraramadevi@hotmail.com

² Asst.Prof.Department of Ophthalmology,
Rangaraya Medical college,Kakinada
drbkjain_mahaveer@yahoo.in

³H.O.D, Department of Ophthalmology,
Rangaraya Medical college,Kakinada
drbkjain_mahaveer@yahoo.in

⁴Post Graduate,Department of Ophthalmology,
Rangaraya Medical college,Kakinada
d.anu_unnagiri@yahoo.com

Abstract: Superior ophthalmic vein thrombosis is rare entity in present antibiotic era. It can be a harbinger of cavernous sinus thrombosis. In its early presentation CST can masquerade as most commonly seen orbital cellulitis.A male patient presented to us with signs of orbital cellulitis who showed improvement with antibiotics except for abduction limitation and headache.MRI showed thrombosis of superior ophthalmic vein and anterior cavernous sinus.After anticoagulant therapy patient recovered.If CST is undetected early on and prompt treatment not given it can lead to life threatening and sight threatening complications.

Keywords: Superior Ophthalmic vein thrombosis, orbital cellulitis,,anticoagulation.

1.Introduction

Superior ophthalmic vein thrombosis is considered to be early sign of cavernous sinus thrombosis.Clinically it is characterized by one sided ptosis,chemosis, ocular restriction and normal fundus examination.^[1] Unilateral thrombosis usually occurs due to local infection from orbit itself or from adjacent paranasal sinuses.^[2] Along with antibiotics, anticoagulants are adjunctive therapy. Although anticoagulant therapy is controversial in these cases it has been reported that early treatment gives good results.^[1]

2. Case Report

A forty year old male patient presented to our OPD with pain, redness, and proptosis of right eye since two days which was associated with severe headache, fever and malaise.On examination of patient there was proptosis of right eye with complete mechanical ptosis due to edema of lids.

Axial proptosis of 28mm of right eye and 21mm of left eye with baseline reading 118 with hertel's exophthalmometer was

recorded.All duction movements in right eye were restricted and painful.Except for severe congestion and grade 3 chemosis of conjunctiva the rest of anterior segment was normal.Posterior segment was also normal.

Having made a provisional diagnosis of orbital cellulitis we started him on intravenous antibiotics (inj ceftriaxone 1gm bd, inj amikacin 1gm bd,inj metrogyl 500mg bd).He was referred to otorhinolaryngeal specialist who suspected sinus pathology and CT scan PNS confirmed spheno-ethmoidal sinusitis.Routine blood investigations showed increase in total count.

After five days of antibiotics there was gross reduction of lid edema, ptosis,chemosis.Except for limitation of abduction all other ductions were full and free.But the patient was still complaining of severe headache and there was no reduction of proptosis.We advised him MRI brain and orbits (plain and contrast) on suspicion of complicating orbital cellulitis.Contrast enhanced MRI revealed filling defect in right

superior ophthalmic vein and bilateral anterior cavernous sinus indicating thrombosis.

After consultation with physician he was started on anticoagulants (sc low molecular wt heparin 0.4mg tid for 5 days, and oral acitram 2mg od for 2 months.)After two week treatment there was significant reduction of proptosis measuring 23mm right eye and 21mm left eye with 118 baseline reading on hertels.He was relieved of headache with improvement in abduction though not complete.He is on regular follow up with vigilant eye on coagulation profile.

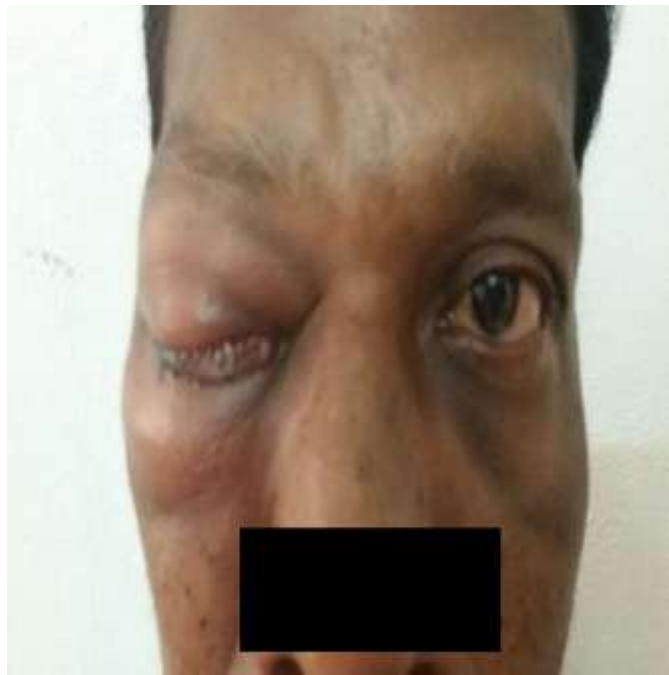

Image 1: Clinical picture at the time of presentation showing proptosis, chemosis and mechanical ptosis.

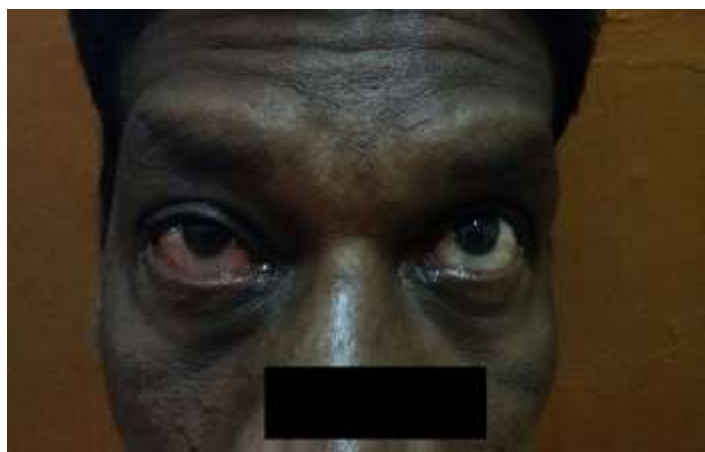

Image 2: Clinical picture after treatment with antibiotics and anticoagulants.

3.Discussion

Orbital infection can be classified as preseptal and postseptal cellulitis.Preseptal cellulitis refers to those infections

localized to eye lids and periocular structures anterior to orbital septum.

The term postseptal cellulitis is used when infectious process is located or extended posterior to orbital septum. In general postseptal cellulitis is more severe and can lead to visual loss.^[3] Most commonly, the infection of orbits originate from sinuses, eyelids, or face. Orbital cellulitis can cause many grave complications such as orbital abscess, orbital vein thrombosis, cavernous sinus thrombosis, meningitis, brain and subdural abscess, carotid occlusion and death.^[2]

Cavernous sinuses receives venous blood from facial veins (via superior and inferior ophthalmic vein) as well as sphenoidal and middle cerebral veins. This complex web of veins contains no valves, blood can flow in any direction depending on the prevailing pressure gradients.^[4] Superior ophthalmic vein appears to be the first pathway of metastasis of ethmoidal sinusitis to cavernous sinus. Infection, trauma, tumor account for approximately 10% cases of cerebral venous thrombosis.^[5] Diagnosis of SOVT is usually made by CT or MRI of head and sinuses. CT shows SOVT as a dilated tubular structure inferior to superior rectus and levator complex. MRI is the imaging modality of choice for confirming SOVT as it shows all stages of thrombus formation.^[3] Parmar et al reported that diffusion-weighted MR may be helpful in cavernous sinus and SOVT by showing restricted diffusion, in addition to correlation of clinical signs and findings of conventional imaging.^[6] Thrombosed vein shows intraluminal signal changes depending on stage of thrombus. Acute thrombus (upto 1 wk) appears isointense in T1 weighted images and hypointense in T2 weighted images.Subacute thrombus shows hyperintensity in both T1- T2 weighted images.^[7]

Septic CST can be acute and fulminant with bilateral ophthalmoplegia.It can also be subacute and more subtle.Headache is most common symptom and is usually presents as sharp forehead and retro orbital pain along distribution of V-1 nerve.[7] Owing to central location of VI nerve in the cavernous sinus, abduction deficit predominates and is also the last to resolve with treatment.^[8] CST requires aggressive intravenous antibiotics treatment.

Anticoagulants is a controversial adjunctive therapy. However, retrospective observations suggest that anticoagulation is beneficial when started early and is recommended when thrombosis remains unilateral.^[7] However, this treatment can

lead to 7-35% hemorrhagic risk, thus the risk of retroperitoneal haemorrhage in particular should be kept in mind and close monitoring of patient is recommended.^[1]

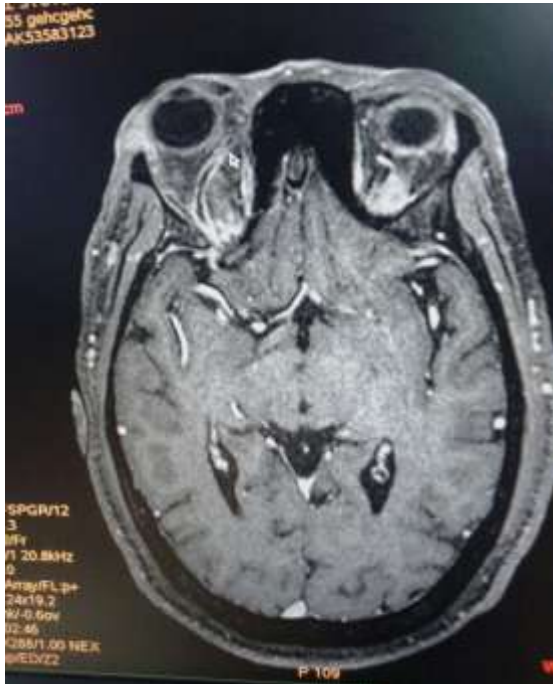


Image:3: Contrast enhanced MRI with gadolinium, arrow showing filling defect in right superior ophthalmic vein.

References

- [1].Tongabay Cumurcu, Soner Demirel, Sinem Keser et al, Superior ophthalmic vein thrombosis developed after orbital cellulitis .Seminars in ophthalmology, 2013;28(2):58-60.
- [2].Shah Devanshi Uday, Suthar Apurva Harendrakumar, Superior ophthalmic vein thrombosis, a grave complication of orbital cellulitis , 2013; 3(7);541-542.
- [3].Vincent B Lam Choi, Hunter K.L Yuen, Jyotirmay Biswas; Update in pathological diagnosis of orbital infections and inflammations; 2011 ;18 (4):268-276.
- [4].Y.Singh, M Singh, SR Saxena, J Kumar, pansinusitis, cavernous sinus thrombosis and cerebral infraction , 2014; 9(2);95-97.
- [5].Sameer Vyas, Palash Jyothi Das, Sunil Kumar Gupta et al;superior and inferior ophthalmic veins thrombosis with cavernous sinus meningioma ; Middle east afr j ophthalmology. 2011 jul-sep; 18(3): 256-258.
- [6].Parmar H, Gandhi D, Mukherji SK, Trobe JD. Restricted diffusion in the superior ophthalmic vein and cavernous sinus in a case of cavernous sinus thrombosis. J Neuroophthalmol. 2009;29:16-20.

[7].Nagarajan K, Sundararajan S;Bilateral superior ophthalmic vein thrombosis in a case of viral meningo-encephalitis; Int J Biosci ,2012; 1(3):45-48.

[8].Christina H. Choe, Jonathan D. Trobe, Case of potentially fatal red eye;2009.