

Clinical Correlative Study Of Posterior Segment Pathology In Blunt Ocular Trauma Using B-Scan Ultrasound

Dr. Ch. Srinivasa Murty¹, Dr. B.K.Vinod Kumar², Dr.N.Ratna Kumari³

¹Associate Professor
Osmania Medical College
Sarojini Devi Eye Hospital
Hyderabad, India
drcsmurty@gmail.com

²Professor
Osmania Medical College
Sarojini Devi Eye Hospital
Hyderabad, India
drcsmurty@gmail.com

³Osmania Medical College
Sarojini Devi Eye Hospital
Hyderabad, India
drcsmurty@gmail.com

Abstract: Ocular trauma is a major cause of worldwide visual impairment. It is the single most important cause of mono ocular blindness worldwide the effect of which is not only on the career and future of the individual but also on the entire family dependent on that earning individual. Worldwide approximately 55 million eye injuries are believed to occur yearly, leaving 1.6 million eyes blind.

Keywords: Ocular trauma . visual impairment, mono ocular blindness.

1. Introduction

One of the most difficult clinical examinations for the ophthalmologists is that of the traumatized globe as the patient may be unable or unwilling to open the lids because of severe pain, and opacification of the anterior chamber, lens or vitreous cavity may further hinder the clinical examination.

B-Scan is the most important routine investigation to be done in cases of blunt ocular trauma, especially in the presence of media opacities like Hyphema, Corneal oedema, Traumatic cataract which are very commonly seen findings of ocular trauma.

This study tries to emphasise the need of B Scan ultrasonography in every first level / District center and need for every Ophthalmologist to be trained in basic ultrasonography techniques because it is a safe non-invasive technique that can be used to detect and differentiate various

traumatic intraocular pathologies and therefore help in decision of the need of referral to higher center and in planning of further line of management[1].

2. Aims and Objectives

To study 50 cases of blunt ocular trauma and correlate the clinical findings with B Scan Ultrasonography.

To confirm the diagnosis of posterior segment pathology in traumatized eyes which is suspected but difficult to diagnose by clinical examination alone.

To study the association and distribution of age, gender, Object of injury.

To study the importance / usefulness of B-Scan USG as a first line mode of investigation in diagnosing the posterior segment pathology in cases of blunt ocular trauma – not only in the

presence of opaque media, but also in the state of relatively clear media, where a complete clinical / fundus examination up to the periphery is not possible – facilitating the plan of management[2].

3. Patients and Methods

It is a descriptive study involving patients presenting to Sarojini Devi Eye Hospital with history of blunt ocular trauma and suspected to have posterior segment pathology on clinical examination.[3]

Sample size :- 50 patients

Study Period :-1 year (Oct 2013 to Sept 2014)

Inclusion criteria :- Cases attending OPD / Emergency Department at Sarojini Devi Eye Hospital with a history of Blunt trauma to Eye

Exclusion Criteria :- Cases with history of previous anterior / posterior segment Pathology.

Cases with history of previous ocular trauma / ocular surgery.

Methodology:-All cases presenting to Sarojini Devi Eye Hospital with history of blunt trauma were clinically examined. Examination was carried out including best corrected VA, pupil examination slit lamp bio microscopy, intra ocular pressure, fundus examination and the relevant general laboratory tests.

The cases with a clinical suspicion / diagnosis of involvement of posterior segment were subjected to B-Scan ultrasonography for the conformation of diagnosis by the contact method.

In contact method the probe is placed directly on the globe (closed lids) to evaluate the posterior segment.

The three basic probe orientations are used to evaluate intra

2. Longitudinal
3. Axial

The probe has a marker (logo / dot / line) that indicates the side of probe represented on upper portion of B-Scan screen display.

Gender	Male	Female
Frequency	43	7
Percentage	86	14
Total	50	100

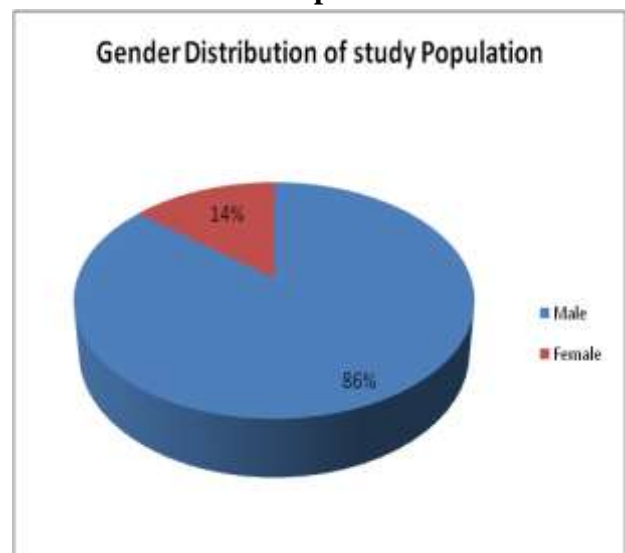
3.1 Statistical Analysis

Data observed in the study are analyzed using computer software. The data are expressed in its frequency and percentage. The data observed is shown in the tables and charts and the statistical results of observations are compared with the statistical results of various other studies done on the similar subject of “Usefulness of ultrasonography in ocular trauma”.

4. Observations and Results

Table 1:Distribution of Gender

Graph 1



Majority of the patients injured in the samples were males(86.00%)

Table 2: Analysis of Age Distribution

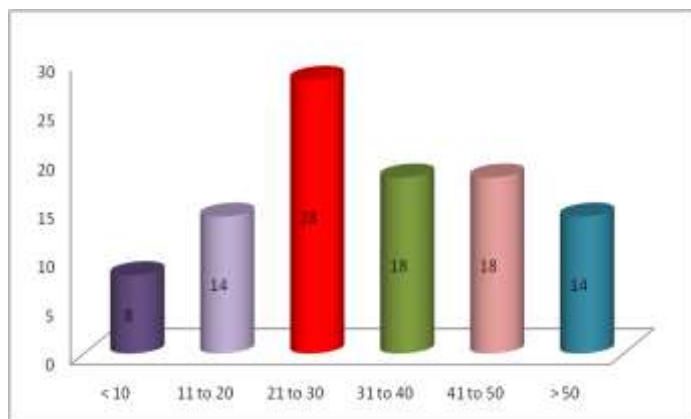
Age in years	Frequency	Percentage
< 10	4	8
11 to 20	7	14
21 to 30	14	28
31 to 40	9	18
41 to 50	9	18
> 50	7	14
Total	50	100

ocular lesions

Table 4: Analysis of Object Causing injury

Mode of injury	Frequency	Percentage
Fist	8	16
Stick	8	16
Ball	7	14
Rod	7	14
Others	7	14
Fall	6	12
Stone	4	8
RTA	3	6
Total	50	100

Graph 2: Age Distribution of Study Population

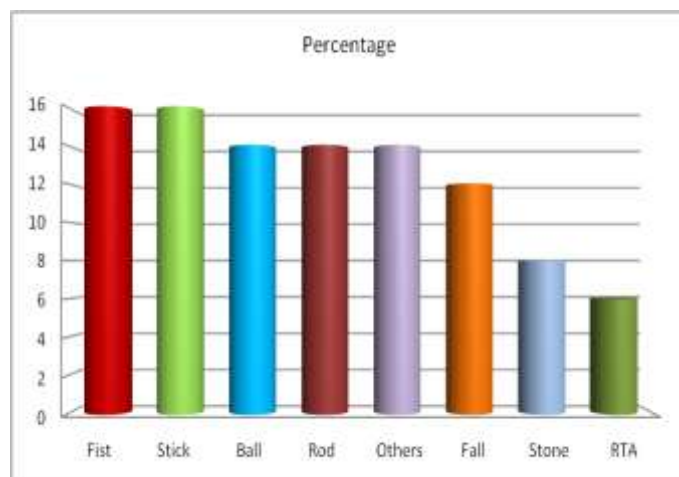


Majority percentage of age group was of 21 to 30 years (28.00%)

Table 3: Analysis of Eye Involved

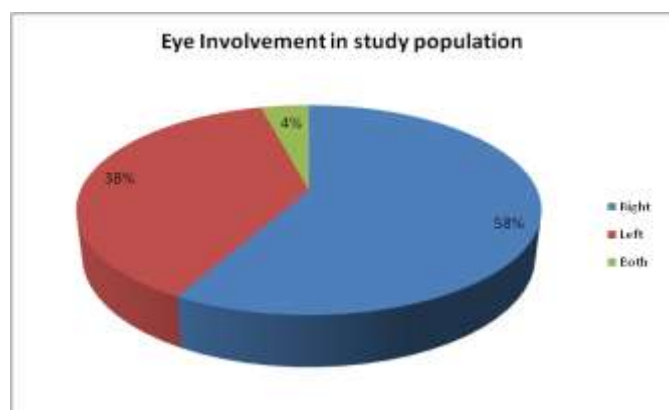
Eye	Frequency	Percentage
Right	29	58
Left	19	38
Both	2	4
Total	50	100

Graph 4 : Object Causing injury



Objects causing injury were almost equally distributed

Graph 3

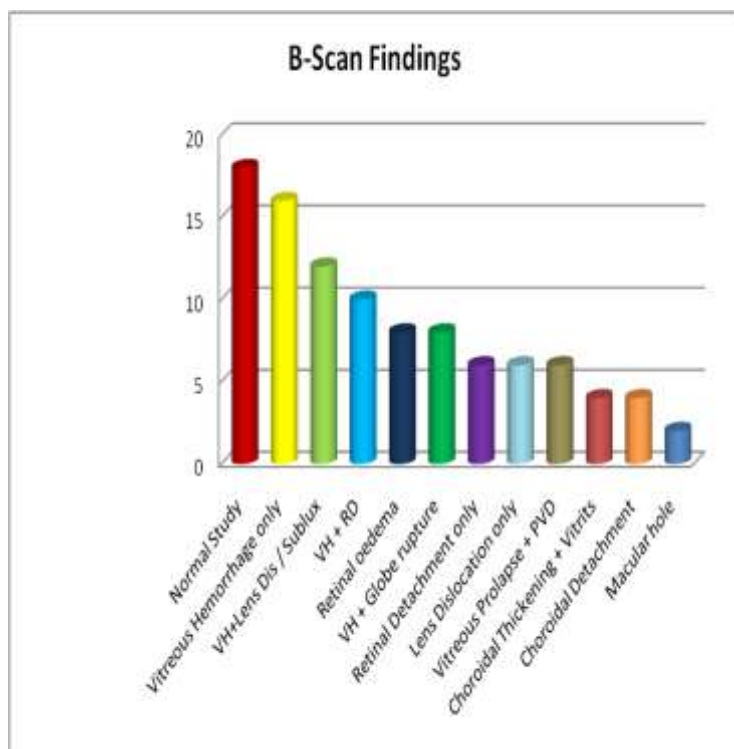


Percentage of right eye (58%) Involvement of right eye(38%)

Table 5: Analysis of B Scan Findings

Pathology	Frequency	Percentage
Normal Study	9	18
Vitreous Hemorrhage only	8	16
VH+Lens Dis / Sublux	6	12
VH + RD	5	10
Retinal oedema	4	8
VH + Globe rupture	4	8
Retinal Detachment only	3	6
Lens Dislocation only	3	6
Vitreous Prolapse + PVD	3	6
Choroidal Thickening + Vitrits	2	4
Choroidal Detachment	2	4
Macular hole	1	2
TOTAL -----	50	100

Graph 5



This study was done with the sample of 50 patients who were suspected to have posterior segment involvement of pathology due to blunt trauma.

Initially all patients with history of blunt ocular trauma were examined clinically and the group of patients who were suspected to have posterior segment pathology, but the diagnosis couldn't be confirmed because of the various anterior segment problem like severe lid oedema, Corneal Oedema, Hyphema more than grade 2 and lenticular opacities were subjected to B-Scan ultrasonography to evaluate the status of invisible posterior segment.

Also the various associations of age, gender, object causing injury were analyzed in relation to the clinical findings of blunt trauma

Out of the 50 cases studied male constituted 43 cases accounting to 86%. The male predominance is because of the social conditions where males are more exposed to the occupational works with higher risks. The male, female ratio in the present study is 80:20.

The study of Badrinath et. Al also showed that 67% of patients exposed to ocular injuries were belonging to the age group around 30 years.

Analysis regarding the object causing injury in present study group shows no specific predominance. The injuries caused by high velocity objects like stones / rod / log of wood showed to be causing more severe damage to the posterior segment (Ex:- Globe rupture and RD).

In a study done at Regional Institute of Ophthalmology , Tiruvanathapuram, showed that the most common mode of closed globe injury was stick / wood constituting 37,33% followed by ball injuries constituting 22,67% correlating well with the study conducted by Michael Ilsar, Moses Chirambo, Abraham and Vitale[4]. Discussion of posterior segment sequelae of blunt trauma diagnosed on B Scan or :

1. Subluxation / Dislocation of lens / IOL.
2. Vitreous haemorrhage.
3. Posterior Vitreous detachment
4. Retinal tear or dialysis
5. Retinal detachment
6. Oedema of retinochoroid layer
7. Haemorrhagic choroidal detachment
8. Posterior scleral rupture / globe rupture
9. Avulsion of optic nerve

5. Discussion

Vitreous haemorrhage:-

In this study vitreous haemorrhage was the most common pathology found in alone in 8 cases, VH in association with lens dislocation / subluxation in 6 six cases, VH with globe rupture in 4 cases, as a total accounting to 46% of cases[5].

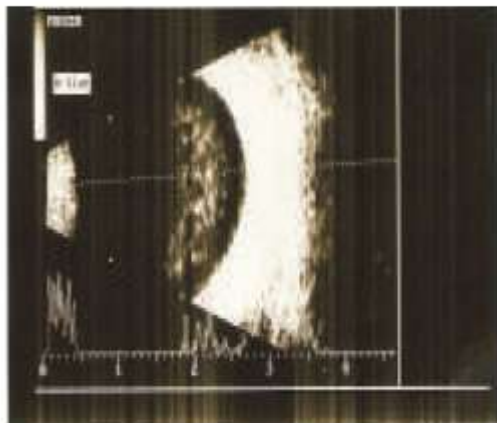


Fig: VH

Figure:- Vitreous haemorrhage

Article IJO on Ultrasonography in ocular trauma states vitreous haemorrhage alone or in combination with posterior subluxated lens, retinal detachment or retained IOFB was seen in 35% of cases in their study.

A study of bed side ultrasonography in emergency department states vitreous haemorrhages can interfere with vision, and if they are large, can lead to apparent blindness. However in the presence of significant facial trauma, it may be difficult to determine the precise cause of decreased visual acuity. Significant Vitreous haemorrhage, Globe rupture, Retrobulber hematomas, lens dislocation can all result in visual loss. Differentiating and diagnosing the above conditions are possible by bed side ultrasonography.

Posterior Vitreous detachment:-

Three cases showed PVD in this study


Retinal detachment:-

Retinal detachment is seen alone in three cases and Retinal detachment with VH seen in 5 cases and RD with traumatic cataract was seen in two cases accounting to a total of 15% in this present study.

The study in IJO named “ultrasonography in ocular trauma” by Tara Prasad das shows that retinal detachment either alone or with other structural abnormalities like

traumatic cataract / dislocated lens , VH was demonstrated in 13% of cases.

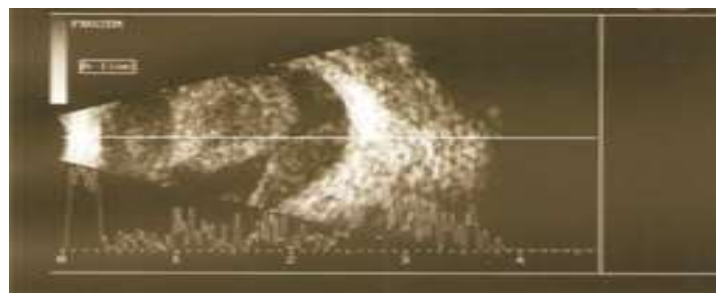
Study of USG evaluation of posterior segment in ocular trauma by Dr.K Harinath in 2005 with a sample group of 50 eyes shows retinal detachment in 12% of cases.



Haemorrhagic choroidal detachment:-

Haemorrhagic choroidal detachment was seen in two cases and choroidal thickening with vitritis was seen in two cases in this study.

In a cross sectional study of USG evaluation of posterior segment in ocular trauma by Dr Harinath also showed a similar incidence of choroidal detachment (6%).



Choroidal detachment

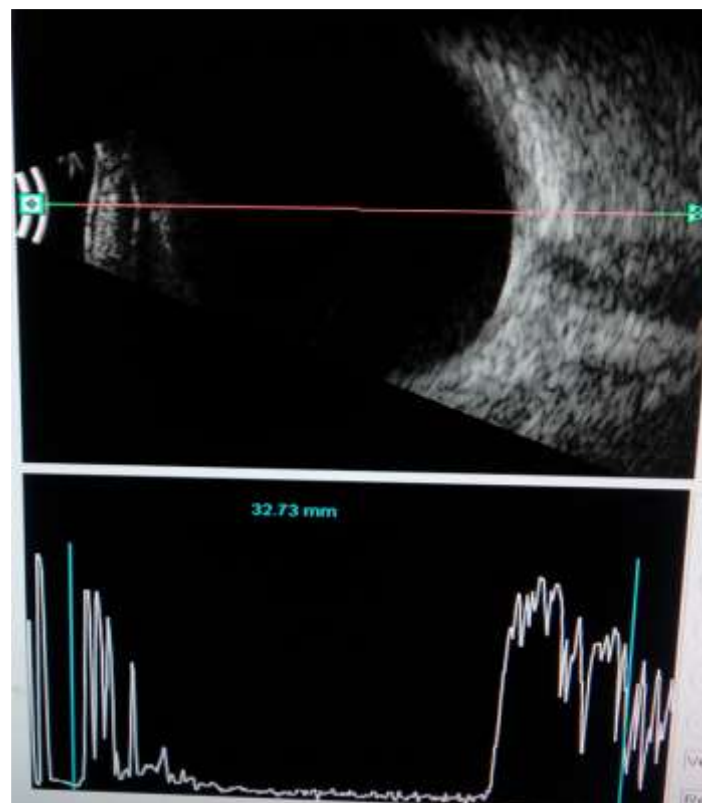
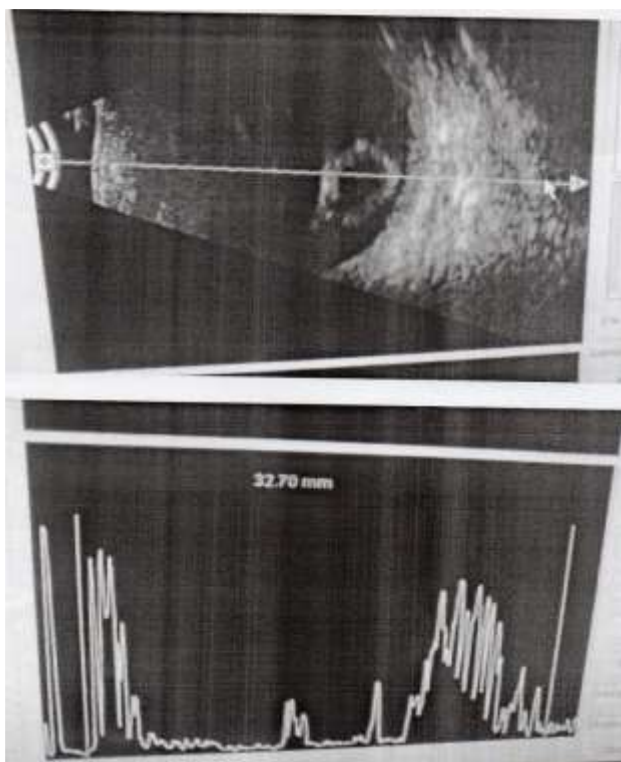
Posterior scleral rupture / globe rupture:-

In this study Globe rupture was seen in four cases of which one had a presenting visual acuity of ? PL and was associated with vitreous haemorrhage and uveal prolapse. The Second case of Globe rupture was associated with vitreous haemorrhage and choroidal detachment with presenting visual acuity of no PL. The other two cases were associated with VH and RD.

Subluxation / Dislocation of lens / IOL:-

In the present study lens dislocation was alone seen in three cases and lens dislocation associated with VH was seen in four cases accounting to a total of 14%.

Posterior Dislocation of lens into Vitreous



Normal Study:-

Out of 50 cases subjected to B-Scan 9 cases showed a normal study of posterior segment. Some of these cases had a Hyphema obscuring the posterior segment view for the clinical / Ophthalmoscopic examination. Though they had a normal study on B-Scan their presenting visual acuity was very poor because of the associated corneal oedema and Hyphema poor visual acuity was the reason to suspect posterior segment involvement which had to be ruled out by B-Scan Ultrasound.

Six cases in our study had a traumatic cataract obscuring the view of posterior segment, and on B-Scan evaluation two of them had a normal study and the other four cases had VH (2) and RD (2). This diagnosis by ultrasonography helps to plan the treatment strategy of these cases and also enables to explain the post surgical visual prognosis to the patients[6].

Normal Study

Out of the 50 cases studied 21 cases had a Hyphema grade 2 and more making the B-Scan examination inevitable to estimate the status of posterior segment on the presenting day. Though many of the traumatic Hyphemas do resolve (observation / medical management) in a period of 4 to 6 days, to an extent where posterior segment examination is possible by ophthalmoscopy, but this delay in coming to a diagnosis can be cut down by doing a B-Scan on the presenting day itself.

In prospective study of 57 eyes done between March to August 2008 at Regional Institute of Ophthalmology to determine the use of B-Scan in diagnosis of vitreoretinal pathologies in blunt ocular trauma with media opacity especially in rural setting showed the results as VH found to be the commonest pathological posterior segment finding with 35 (61.4%) followed by PVD 15 (26.3%) , retinal detachment 7 (12.3%), Subluxated lens 5 (8.8%) and haemorrhagic choroidal detachment 4 (7%) well correlating with the results of our present study.

CONCLUSION

Although the eyes represent 0.1% of the total body surface and only 0.27% of the anterior body surface, their significance to individuals and society is disproportionately high.

Ultrasound has revolutionized the management of the traumatized eyes, by providing Ophthalmologist with an

instantaneous look into an acute traumatized eye, where complete clinical examination is not easy.

The cystic composition and superficial position makes the eye ideal for ultrasound examination.

Ultrasound is cheap, noninvasive, non-ionizing, easily available, rapid, portable, harmless modality of investigation.

It is the best first-line investigation to detect and differentiate various traumatic intraocular pathologies and therefore guide in planning of further line of management.

CT scan is expensive, non-available at peripheral centers, time taking and can be done only by a Radiologist unlike the B-Scan, which can be done by a trained Ophthalmologist even in a peripheral / rural setup.

In this study 50 patients are evaluated for posterior segment pathology by ultrasound and 100% accurate diagnosis was possible[7].

Ultrasound was the most practical method of obtaining the images of posterior segment of eye, specially when the light conducting media is opaque. (Corneal oedema, Hyphema, Cataract)

The accurate diagnosis obtained by ultrasound examination on the presenting day of trauma is very useful in cutting down the delay that can be caused due to the anterior segment pathologies to resolve after which only a clinical examination can give a complete diagnosis.

Limitations:- However, as mentioned in article of “USG in ocular trauma” by Jyothi Prakash Vyas the limitations/disadvantages of ultrasonography are

Because ultrasound requires direct contact with the eye lids and /or globe, it should not be used in eyes with a high risk of extrusion of intraocular contents (Large wound, uncooperative patient). In these cases echography can be performed in the operating room after the globe has been closed and the patient is under general anesthesia.

Ultrasound examination requires technical skill, training, experience and sound judgment to be a reliable test.

It is not useful in diagnosing orbital fractures.

False positive results may be found in the presence of gas bubbles.

It is limited in its ability to distinguish between different materials of IOFB.

B-Scan tends to overestimate the size of IOFB and should not be used for measuring purposes.

However not withstanding with these limitations The usefulness of B-Scan Ultrasonography confirms its requirement in every peripheral district center and also the need for all Ophthalmologists to be trained in ultrasonography techniques. This can rationalize the timely needed referrals of trauma cases to higher centers for a better line of management [8].

REFERENCES

- [1].Dr. Raju K V M S, Dr Nima C A MS, Dr Anju A K MS, Closed globe injuries – A Tertiary Care Experience: Kerala Journal of Ophthalmology, March 2009; 21(1);25-30.
- [2].Negrel AD, Thylefors B. The Global impact of eye injuries . *Ophthalmic Epidemiology* 1998; 5;143-169.
- [3].Coleman DJ, Lizzi FL, Jack RL: *Ultrasonography of the eye and Orbit*. Philadelphia, Lea & Febiger 1977, p 248
- [4].Green RL, Byrne SF; Diagnostic Ophthalmic Ultrasound in Ryan SJ (ed) ; *Retiana*. St Louis, Mosby, 1989, page 234.
- [5].Usefulness of B-Scan Ultrasonography in Ocular Trauma, original article, Pratap Rai, Syeed imtiaz Ali Shah, Alyscia M.Cheema, Javed Hassan Niazi, Shahid Jamal Siddiqui, Pak J. Ophthalmal 2007, Vol 23 No 3.
- [6].Coleman DJ; Reliability of ocular and orbital diagnosis with B Scan Ultrasound.1.Ocular diagnosis. *Am J Ophthalmol* 1972;73;501
- [7].Scott IU, Smiddy WE Feuer WJ study of impact of echography in evaluation and management of posterior segment disorders. *American journal of Ophthalmology* 2004 Jan 137 (24 -29)
- [8].Evaluation of Ultra sound efficiency in diagnosing traumatized eyes in Sudan – Dr Elsafi Ahmad Abdulla – July 2010 to Dec 2010 – Makka Hosp in Khartoum.

