

Rare case of super-response to Cardiac Resynchronization Therapy in Macedonian patient with Dilated Left Ventricular Non-Compaction Cardiomyopathy

B. Shopov¹; P. Zafirovska²; J. Kostov¹; N. Manev¹; A. Georgiev¹

¹ University Clinic of Cardiology, Skopje, North Macedonia

² Zan Mitrev Clinic, Skopje, North Macedonia

Abstract:

Background: Left ventricular non-compaction (LVNC) is rare cardiomyopathy with increased and prominent endomyocardial trabeculations also known as spongy myocardium. It is often found in association with a dilated cardiomyopathy (DCM) and has high incidence of Heart failure (HF). Cardiac resynchronization therapy (CRT) is currently recommended by the available guidelines for selected patients with Heart failure with reduced ejection fraction (HFrEF).

Aim: Our case report aims to highlight the therapeutic benefits and superresponse to CRT in a patient with Left ventricular non-compaction cardiomyopathy and HFrEF.

Case report: 55-year-old Macedonian male patient with HFrEF, Left bundle branch block (LBBB) remained symptomatic (NYHA III) despite optimal medical treatment (OMT). Echocardiography and CMR findings were in addition to dilated and left ventricular non-compaction cardiomyopathy. Cardiac resynchronization therapy was indicated and 18 months after implantation of CRT-P device we have achieved complete and utter reversibility of systolic myocardial function (EF from 23% to 53%), left ventricular internal diameter was reduced from 90mm to 64mm, left ventricular end systolic volume (LVESV) was reduced from 319ml to 98ml and patient quality of life significantly improved.

Conclusion: Cardiac resynchronization therapy is a safe and valuable method of treatment for patients with HFrEF due to dilated left ventricular non-compaction cardiomyopathy.

Introduction:

Heart failure with reduced ejection fraction (HFrEF) remains a significant cause of morbidity and mortality worldwide, despite advancements in medical therapy. Isolated left ventricular non-compaction (LVNC) is rare congenital cardiomyopathy characterized by excessively prominent trabeculations and deep intertrabecular recesses in the left ventricular myocardium. LVNC cardiomyopathy has high incidence of heart failure (HF) and is often associated with dilated cardiomyopathy (DCM) and poses therapeutic challenges due to its complex pathophysiology.^{1,2} Because of the lack of large studies, it is still unclear whether LVNC patients would benefit from cardiac resynchronization therapy (CRT).

Cardiac resynchronization therapy (CRT) is a pivotal treatment option for select patients with heart failure with reduced ejection fraction (HFrEF), particularly those with left bundle branch block (LBBB) and evidence of ventricular dyssynchrony who are symptomatic despite optimal medical therapy (OMT). CRT in these patients can improve not only clinical status (NYHA functional class, quality of life, and exercise capacity) but also left ventricular (LV) function, with reverse LV remodelling, and decreases hospitalization. However, clinical response to CRT is variable.³⁻⁷ Herein, we present a rare case of a successful cardiac resynchronization therapy in 55-year-old male patient with heart failure with reduced ejection fraction (HFrEF) and dilated left ventricle with non-compacted myocardium.⁶

Case report:

Fifty-two-year-old man – presenting with shortness of breath and fatigue for the past 3 years despite optimal medical therapy asked for medical advice in our clinic.

He was classified as NYHA (New York Heart Association) Class III based on his symptoms. His electrocardiogram (ECG) revealed sinus rhythm with morphology of LBBB with QRS duration >140ms, left axis deviation, fr. 70/min, ST segment and T waves changes within the morphology of LBBB. Echocardiography revealed severe LV enlargement (LVIDd 90mm, LVIDs 77mm, LVEDV 450ml, LVESV 319ml) with impaired systolic function LVEF 29%, moderate mitral regurgitation, trabeculations at the upper third of the lateral wall and apex of the left ventricle and left ventricular non-compaction cardiomyopathy was suspected.

Further, cardiac magnetic resonance (CMR) findings consisted of dilated LV with reduced systolic function LVEF 23%, LVEDV 379ml, LVESV 291ml, global left ventricular hypokinesia, dyssynchrony of the interventricular septum and moderate mitral regurgitation.

CMR also demonstrated LV trabeculations in the upper third of the lateral wall and the apex of the heart. After assessing each of three diastolic long-axis cine MR images, ratio of non-compacted to compacted myocardial thicknesses (NC/C ratio) was 2.3 which, based on Petersen et al's CMR criteria², CMR findings can go in addition to Left ventricular non-compaction cardiomyopathy (LVNC). There was no late gadolinium enhancement (LGE) in the myocardium. Along with these results, we suggested DCM with LVNC, and CRT was indicated (Images 1&2)

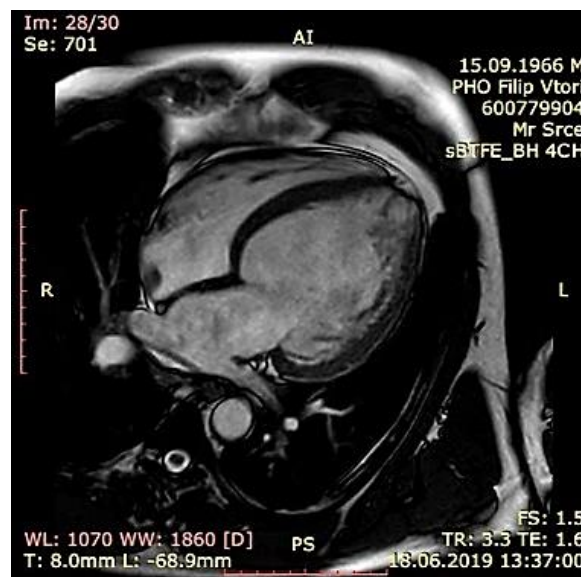

image 1: CMR before CRT-P implantation.

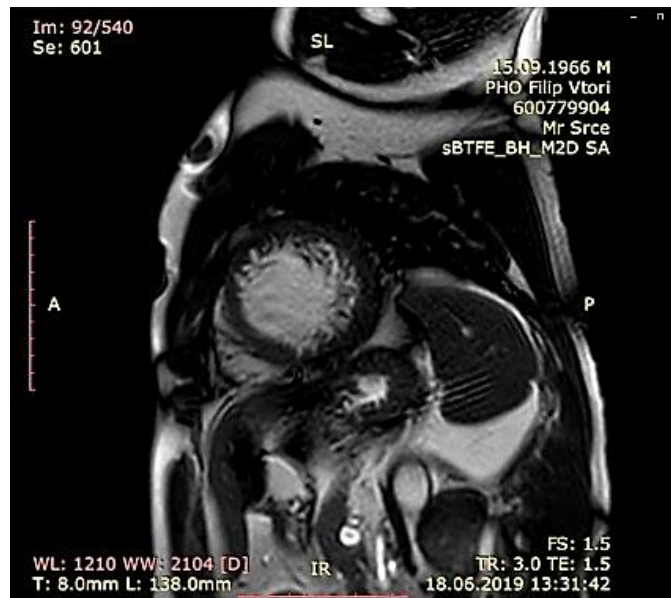

image 2: CMR short axis apical view before CRT implantation.

CRT-P “Abbott (St Jude Medical) Quadra Allure 3562 CRT-P pacemaker” was implanted in Zan Mitrev Clinic and the interrogation on the device confirmed appropriate normal function with adequate stimulation of the heart – continuous synchronized biventricular (DDDR) and atrioventricular (AV) synchronized (AsVp) mode for stimulation/pacing.

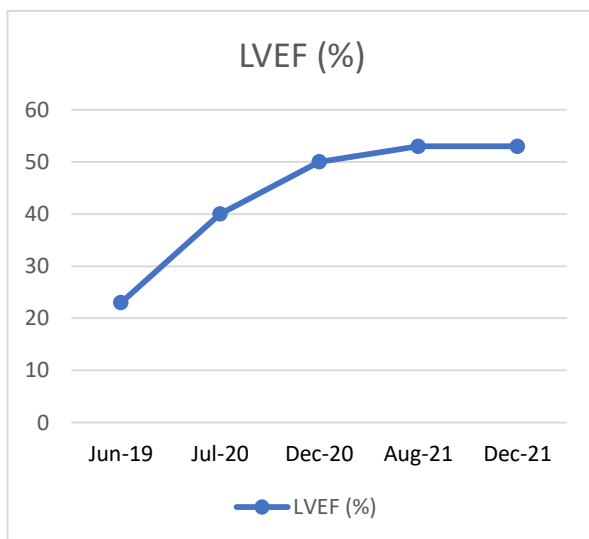


Fig. 2: demonstrate the improvement of the left ventricular ejection fraction over the period before and after the implantation of the CRT-P.

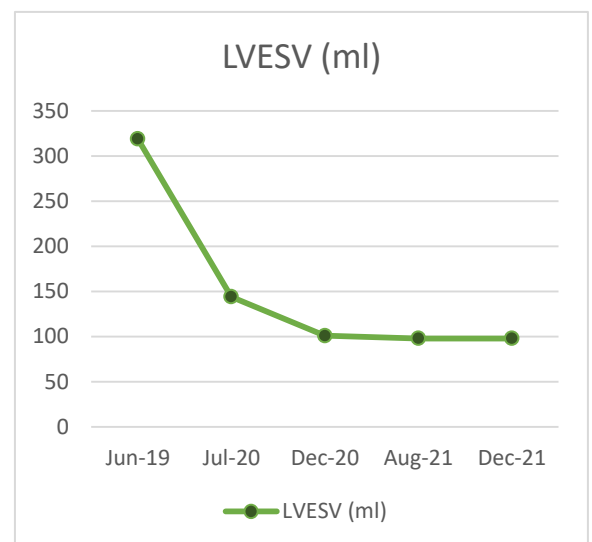


Fig. 1: demonstrate the reduction in left ventricular end systolic volume after the implantation of CRT-P.

Further patient was followed, and echocardiographic examination performed after one year revealed significant improvements in both the LV ejection fraction and as well significant reduction in LV enlargement (LVIDd 68mm, LVIDs 54mm, LVEDV 239ml, LVESV 144ml). The latest follow-ups done in August and December 2021 showed improvement in the LVEF to 53% and further decrease in LV dimensions (LVIDd/LVIDs 64/46mm, LVESV 98ml). Patient reported significant improvement of symptoms and was classified as NYHA I. (Figure 1-3, Image 3)

Discussion:

Our case illustrates the therapeutic potential of CRT in patients with HFrEF secondary to LVNC cardiomyopathy. LVNC can manifest in isolation or coexist with other cardiac conditions, such as DCM, as observed in our patient. The pathogenesis of LVNC involves disruptions in myocardial compaction during embryogenesis, leading to a spongy appearance and hypertrabeculation of the left ventricular myocardium and impaired systolic function.^{1,8} The clinical spectrum of LVNC ranges from asymptomatic individuals to those presenting with heart failure, arrhythmias, or thromboembolic events, underscoring the importance of comprehensive evaluation and tailored management strategies². In our case, the patient exhibited symptomatic heart failure despite optimal medical therapy, prompting consideration for CRT. The decision to pursue CRT was supported by the presence of LBBB on electrocardiogram (ECG) and evidence of left ventricular dyssynchrony on echocardiography and cardiac magnetic resonance imaging (CMR). CRT aims to improve cardiac function and symptoms by coordinating ventricular contraction through synchronized pacing of the left and right ventricles.

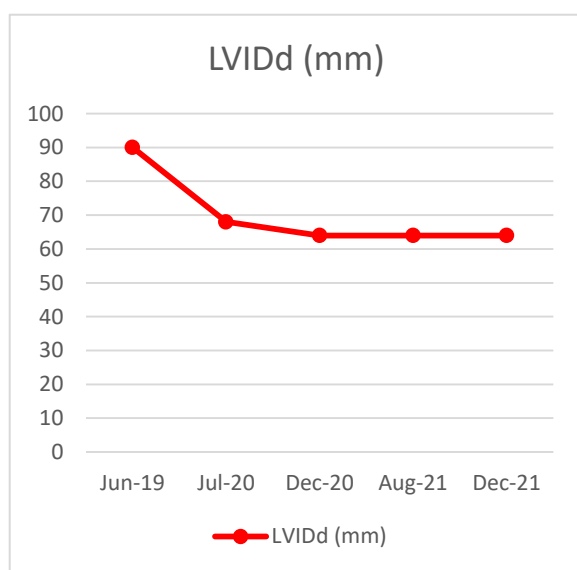


Fig. 3: demonstrate the reduction in left ventricular internal dimension in diastole over the course of treatment.

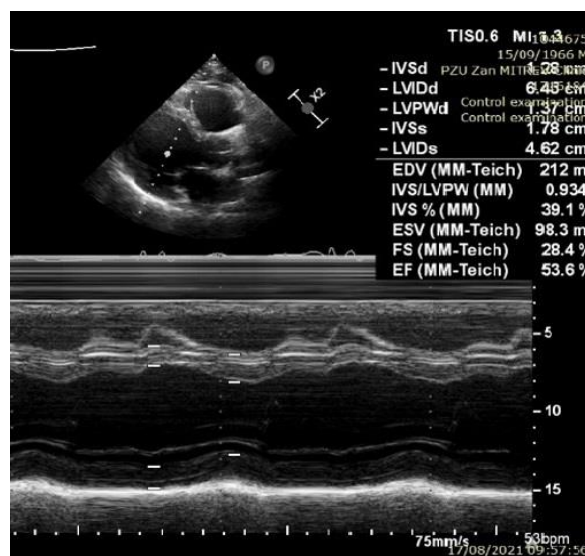


image 3: TTE 18 months after implantation of CRT-P which demonstrates the improvement of left ventricular ejection fraction.

We presented a rare case report of super-response to cardiac resynchronisation treatment in a patient with heart failure with reduced ejection fraction (HFrEF) due to dilated left ventricular non-compaction (LVNC) cardiomyopathy. In our patient, despite left ventricular non-compacted myocardium CRT-P treatment resulted in the improvement in the LV function (from 23% to 53% EF), reduction in left ventricular internal diameter from 90mm to 64mm, reduction of left ventricular end systolic volume (LVESV) from 319ml to 98ml and improvement in clinical symptoms and NYHA classification from NYHA III to NYHA I.

Randomised controlled trials and meta-analyses have revealed that CRT reduces morbidity and mortality in appropriately selected patients with heart failure with reduced ejection fraction (HFrEF) and LBBB.⁹⁻¹¹. In a large trial called "CRT Survey II", none of the 10692 patients undergoing CRT implantation was diagnosed with LVNC CMP. Therefore, this case is a rare example of excellent echocardiographic and functional response to CRT in patient with dilated left ventricular non-compaction CMP and heart failure with reduced ejection fraction.^{6,12} The effects of CRT on left ventricular remodeling and dyssynchrony in LVNC-associated HFrEF remain a topic of investigation. The results from the studies by Towbin et al.¹³, Qiu et al.¹⁴, Oginozawa et al.¹⁵, and Peix et al.¹ provide valuable insights into the impact of cardiac resynchronization therapy (CRT) on left ventricular function and remodeling in patients with left ventricular non-compaction (LVNC).

Towbin et al. conducted a comprehensive review highlighting the clinical features, diagnostic criteria, and management strategies for LVNC. They emphasized the importance of accurate diagnosis and risk stratification in guiding therapeutic interventions, including CRT, in patients with LVNC.¹³ Qiu et al. evaluated the effects of CRT on left ventricular remodeling and dyssynchrony in patients with LVNC and heart failure. Their study demonstrated significant improvements in left ventricular function and synchronization following CRT, with reductions in left ventricular volumes and improvements in ejection fraction.¹⁴

Oginozawa et al. reported on the effect of CRT in isolated ventricular non-compaction in adults, providing insights into the clinical outcomes of CRT in this patient population. Their follow-up of four cases demonstrated improvements in symptoms, left ventricular function, and clinical outcomes following CRT implantation.¹⁵

Peix et al. assessed intraventricular synchronism using gated-SPECT myocardial perfusion imaging in patients undergoing CRT, with a focus on the influence of cardiomyopathy type on treatment outcomes. Their study revealed that patients with LVNC experienced comparable improvements in intraventricular synchronism and left ventricular function following CRT compared to those with other cardiomyopathies.¹⁸

The results from these studies collectively highlight the therapeutic benefits of CRT in patients with LVNC, including improvements in left ventricular function, reverse remodeling, and symptomatic relief.

Conclusion:

Implantation of a cardiac-resynchronization device like CRT-P improves symptoms and left ventricular function in HFrEF patients with dilated and left ventricular non-compaction cardiomyopathy. Cardiac resynchronisation therapy is a safe and successful method of treatment for patients with HFrEF due to dilated left ventricle with non-compacted myocardium.

References:

1. Peix A, Padrón K, Cabrera LO, et al. Intraventricular synchronism assessment by gated-SPECT myocardial perfusion imaging in cardiac resynchronization therapy. Does cardiomyopathy type influence results? *EJNMMI Research*. 2020;10(1). doi:10.1186/s13550-020-00703-4
2. Choi Y, Kim SM, Lee SC, Chang SA, Jang SY, Choe YH. Quantification of Left ventricular trabeculae using cardiovascular magnetic resonance for the diagnosis of Left ventricular noncompaction: Evaluation of trabecular volume and refined semi-quantitative criteria. *Journal of Cardiovascular Magnetic Resonance*. 2016;18(1):1-13. doi:10.1186/s12968-016-0245-2
3. Hoshiya Y, Sugimoto A, Doi S, et al. Discontinuation of cardiac resynchronization therapy for heart failure due to dilated cardiomyopathy in a 61-year-old female “super-responder” with return of a reduced left ventricular ejection fraction to normal. *American Journal of Case Reports*. 2020;21:1-5. doi:10.12659/AJCR.926704
4. McDonagh TA, Metra M, Adamo M, et al. 2021 ESC Guidelines for the diagnosis and treatment of acute and chronic heart failure. *European Heart Journal*. 2021;42(36):3599-3726. doi:10.1093/eurheartj/ehab368
5. Glikson M, Nielsen JC, Kronborg MB, et al. 2021 ESC Guidelines on cardiac pacing and cardiac resynchronization therapy. *European Heart Journal*. 2021;42(35):3427-3520. doi:10.1093/eurheartj/ehab364
6. Normand C, Linde C, Bogale N, et al. Cardiac resynchronization therapy pacemaker or cardiac resynchronization therapy defibrillator: What determines the choice? - Findings from the ESC CRT survey II. *Europace*. 2019;21(6):918-927. doi:10.1093/europace/euz002
7. Steffel J, Ruschitzka F. Superresponse to cardiac resynchronization therapy. *Circulation*. 2014;130(1):87-90. doi:10.1161/CIRCULATIONAHA.113.006124
8. Peix A, Karthikeyan G, Massardo T, et al. Value of intraventricular dyssynchrony assessment by gated-SPECT myocardial perfusion imaging in the management of heart failure patients undergoing cardiac resynchronization therapy (VISION-CRT). *Journal of Nuclear Cardiology*. 2021;28(1):55-64. doi:10.1007/s12350-018-01589-5
9. Erdmann E, Freemantle N, Ph D, Gras D, Kappenberger L, Tavazzi L. The effect of cardiac

- resynchronization on morbidity and mortality in heart failure: Comments. *Indian Heart Journal*. 2005;57(2):186. doi:10.1111/j.1527-5299.2005.04176.x
10. Ghio S, Freemantle N, Scelsi L, et al. Long-term left ventricular reverse remodelling with cardiac resynchronization therapy: Results from the CARE-HF trial. *European Journal of Heart Failure*. 2009;11(5):480-488. doi:10.1093/eurjhf/hfp034
 11. Dickstein K, Normand C, Auricchio A, et al. CRT Survey II: a European Society of Cardiology survey of cardiac resynchronisation therapy in 11 088 patients—who is doing what to whom and how? *European Journal of Heart Failure*. 2018;20(6):1039-1051. doi:10.1002/ejhf.1142
 12. Taborsky M, Skala T, Aiglova R, et al. Cardiac Resynchronization and Defibrillator Therapy (CRT-D) or CRT Alone (CRT-P) in patients with dilated cardiomyopathy and heart failure without late gadolinium enhancement (LGE) cardiac magnetic resonance imaging (CMRI) high-risk markers - CRT-REALITY . *Biomedical Papers*. 2021;(Icd). doi:10.5507/bp.2021.015
 13. Towbin JA, Lorts A, Jefferies JL. Left ventricular non-compaction cardiomyopathy. *The Lancet*. 2015;386(9995):813-825. doi:10.1016/S0140-6736(14)61282-4
 14. Qiu Q, Chen Y, Mai J, et al. Effects of cardiac resynchronization therapy on left ventricular remodeling and dyssynchrony in patients with left ventricular noncompaction and heart failure. *The international journal of cardiovascular imaging*. 2015;31(2):329-337. doi:10.1007/s10554-014-0568-8
 15. Oginosawa Y, Nogami A, Soejima K, et al. Effect of Cardiac Resynchronization Therapy in Isolated Ventricular Noncompaction in Adults: Follow-Up of Four Cases. *Journal of cardiovascular electrophysiology*. 2008;19:935-938. doi:10.1111/j.1540-8167.2008.01161.x

Patient consent

We declare that we have signed informed consent from the patient.